

A Multiple-Case Study of Atraumatic Extraction and Collagen-Plug Management in Patients with Cigarette Smoking

Chen-Che Hung*

Mediterranean Prosthodontic Institute, Castellon, Spain

Private Practice, Kaohsiung, Taiwan

Citation: Hung CC. A Multiple-Case Study of Atraumatic Extraction and Collagen-Plug Management in Patients with Cigarette Smoking. *Journal of Dentistry and Dental Materials* 2025;1(1):04-07.

Received: 28 September, 2025; **Accepted:** 13 October, 2025; **Published:** 15 October, 2025

***Corresponding author:** Chen-Che Hung, Mediterranean Prosthodontic Institute, Castellon, Spain, Email: periov@icloud.com

Copyright: © 2025 Hung CC., This is an open-access article distributed under the terms of the Creative Commons Attribution License, which permits unrestricted use, distribution, and reproduction in any medium, provided the original author and source are credited.

A B S T R A C T

Tooth extraction is a very common oral surgery procedure in clinical practice. The wound healing process should be managed based on the patient's condition. Cigarette smoking is one of the risk factor that may induce post-treatment complications such as dry socket (alveolar osteitis) and adjacent gingival tissue inflammation. Regenerative collagen matrix and other grafting materials are suggested to insert into the extracted socket to reduce hemorrhage, facilitate clot formation, and preserve the most amount of alveolar ridge as one of the techniques of alveolar ridge preservation (ARP). As the properties of collagen matrix promote clot formation, it is also recommended to use biomaterials in patients taking anticoagulants and antiplatelet medications to decrease the risk of continuing bleeding after the exodontia.

Keywords: Cigarette smoking; Atraumatic extraction; Collagen plug; Wound healing

Introduction

Cigarette smoking is one of a habit that could implicate nearly every human organ system nowadays¹. Conditions such as heart disease, respiratory disease, oral disease, and cancer have high relations with the usage of these tobacco and nicotine products^{1,2}. Wound healing is a challenge in patients with smoking habits due to the chances of damaging healing mechanisms and clot formation in tooth extraction². These impairments may increase the chances of alveolar osteitis in the post-extraction stage^{2,3}. To minimize the risk of post-treatment complications, the method of atraumatic extraction and the usage of collagen plugs are recommended⁴⁻⁷.

Atraumatic extraction proceeds to extract the tooth with caution and decreases surgical trauma and tissue laceration and lowers the chance of post-operative pain⁷. Specific instruments such as desmotome, periotome, mini elevators, Benex® extraction system, and piezoelectric surgery unit could be selected to perform the procedure^{6,8-11}. The purpose of the method is to preserve adjacent tissues and only remove inflammatory

structures including the tooth, granulated tissue and necrotic defects in flapless design^{6,7}. Periodotome as an aid to the extraction has been confirmed to lower the post-operative pain and the rate of complications by detaching the tooth from the socket through periodontal ligament space⁸. Adequate extraction force could be provided using the Benex® extraction system to prevent unnecessary damage to the adjacent structure and the piezoelectric device could allow the clinicians to perform minimally invasive surgery to extract the tooth while preserving the alveolar ridge⁹⁻¹¹.

As a result of the bone remodeling phase after tooth extraction, the alveolar ridge resorption is inevitable and may lead to inadequate hard and soft tissue envelope^{7,12-14}. Various alveolar ridge preservation (ARP) are proposed and involved the usage of hemostatic agents and biomaterials^{12,14,15}. The socket-plug technique is one of the most conventional and easy-to-manipulate methods in ARP^{5-7,16}. A selected socket-shaped collagen plug is inserted into the extracted socket after the debridement of the wound⁵⁻⁷. It has been confirmed that the collagen plug could maintain the volume of the alveolar ridge

and the patient feels less pain compared to spontaneous healing of the socket^{5,7,17}. The biomaterial benefits clot formation and proclaims better wound healing results^{7,13,17}.

This multiple-case study aims to compare the management of the biomaterials and spontaneous healing in patients with cigarette smoking requesting tooth extraction under a minimally invasive extraction method.

Clinical Reports

Three clinical cases were presented in Grand Hyatt Dental Clinic, Kaohsiung City, Taiwan with a request for lower right molars extraction. All of them proceeded with the atraumatic extraction procedure and wound management following its situation. Two cases involved patients with cigarette smoking and betel quid chewing and the other one involved the patient with cigarette smoking and taking antiplatelet agents.

Case 1 - Cigarette Smoking (+) / Betel Quid Chewing (+) - Spontaneous Healing

A 41-year-old male sought lower right 1st molar extraction due to the presence of mobility (**Figure 1A**). The patient has been smoking for more than 10 years and takes 10 cigarettes per day. He proclaimed he has reduced the amount of betel quid chewing and only chew it while driving. No signs of infection or pain were presented. The 1st molar was detached from periodontal tissue using desmotome and periotome (Desmotome/ Periotome, HELMUT ZEPF MEDIZINTECHNIK GMBH, Seitingen-Oberflacht, Germany) and extracted using a curved elevator (X-LUXA-TOOL Curved Elevator 2.5mm, HELMUT ZEPF MEDIZINTECHNIK GMBH, Seitingen-Oberflacht, Germany). The residual granulated tissue was curetted and removed from the socket (**Figure 1B**). The wound was irrigated with normal saline and two gelatin sponges (ROEKO Gelatamp 14 x 7 x 7 mm, Coltène/Whaledent AG, Altstätten, Switzerland) were placed separately into the socket (**Figure 1C**). The wound healing was recorded after 7 days (**Figure 1D**). Gingival tissue infiltrated into the distal socket and the alveolar ridge resorption is observed.

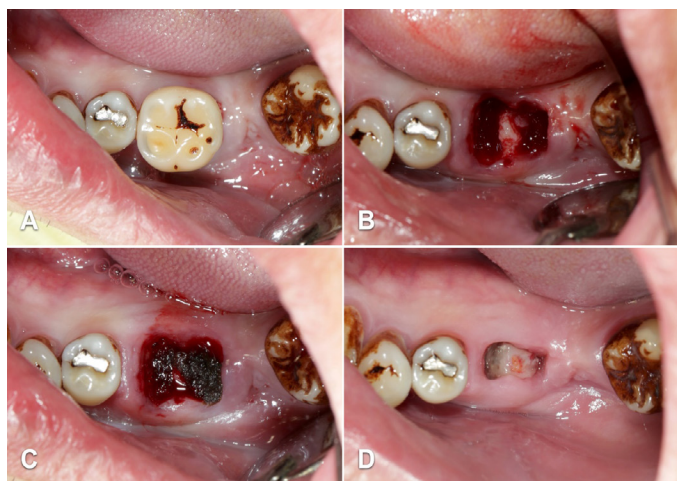


Figure 1: Lower right 1st molar extraction with spontaneous healing. (A): Initial of lower right 1st molar. (B): The 1st molar was extracted under the method of atraumatic extraction. Granulated tissue presented on top of interradicular septum. (C): Granulated tissue was removed and two gelatin sponges were inserted separately into the extracted socket. (D): 7 days F/U record.

Case 2 - Cigarette Smoking (+) / Betel Quid Chewing (+) - Socket-Plug Technique

A 47-year-old felt hypersensitivity and tooth mobility of his lower right 1st molar (**Figure 2A**). The patient has serious attrition problems due to the betel quid chewing habit. The patient smokes nearly 1 pack of cigarette and chews half pack of betel quid per day. No signs of infection or pain were presented. The 1st molar was detached from periodontal tissue using desmotome and periotome in order to loosen the roots and then extracted under the atraumatic method (**Figure 2B**). The socket-plug technique is used with collagen plug wound dressing (Horien® Gennu-Plug \varnothing 8.3mm x 20mm, HORIEN Biochemical Technology Co. Ltd, Taichung City, Taiwan) and sutured with 4-0 silk conventional crossed mattress suturing to hold the collagen once the granulated tissue was curetted (**Figure 2C**). The suture was removed and the wound healing was recorded after 7 days (**Figure 2D**). The wound was almost sealed and healed. Both gingival tissue and alveolar ridge volume are preserved.

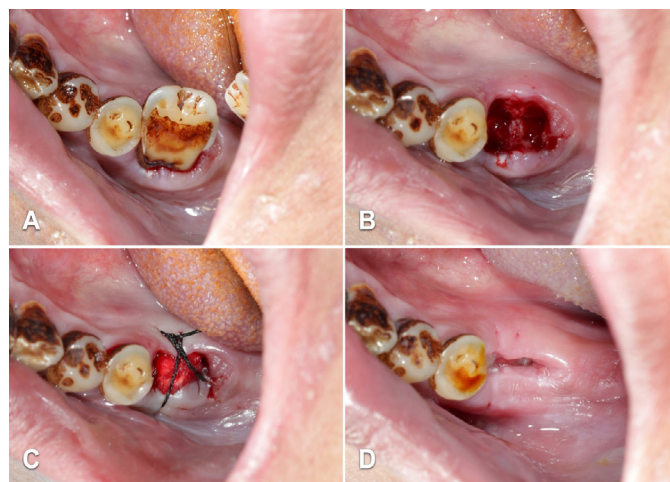


Figure 2: Lower right 1st molar extraction with the socket-plug technique. (A): Initial of lower right 1st molar. Severe tooth attrition was noticed. (B): The 1st molar was extracted under the method of atraumatic extraction. Granulated tissue was removed and normal saline irrigation was applied. (C): Horien® Gennu-Plug collagen plug was inserted and conventional crossed mattress suturing sealed the wound following the socket-plug technique. (D): Suturing removal after 7 days and then record.

Case 3 - Cigarette Smoking (+) / Antiplatelet Agent (+) - Socket-Plug Technique

A 46-year-old requested lower right 2nd molar extraction due to deep cervical root caries and food stuck into interproximal contacts (**Figure 3A**). Grade II mobility presented and caused pain while biting. The patient has been taking Aspirin (Bokey EM cap 100mg, YSP) for more than two years and reduces smoking by about 2 to 3 cigarettes per week. The tooth extraction was performed under American Dental Association (ADA) guidelines for the management of oral anticoagulant and antiplatelet medications. The 2nd molar was detached from periodontal tissue using desmotome and periotome and extracted using a 2.5mm curved elevator (**Figure 3B**). The wound was debrided and retained the clot inside the socket by inserting Horien® Gennu-Plug wound dressing then sutured with 4-0 silk conventional crossed mattress (**Figure 3C**).

The suture was removed and the wound healing was recorded after 7 days (**Figure 3D**). The alveolar ridge is maintained and no post-operative complication was reported.

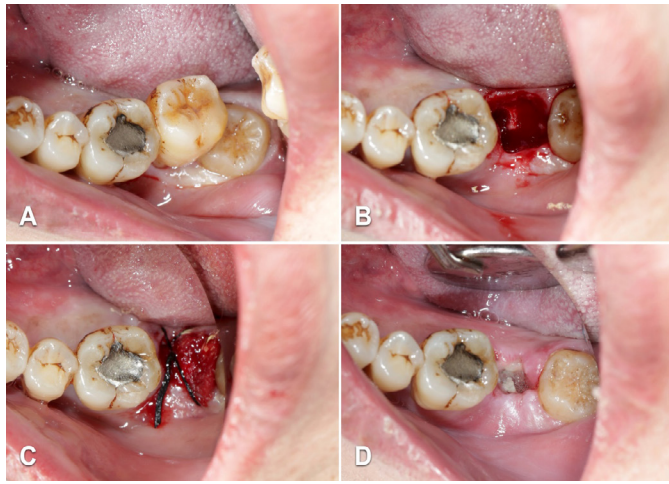


Figure 3. Lower right 2nd molar extraction with the socket-plug technique. (A): Initial of lower right 2nd molar. (B): The 2nd molar was extracted and interradicular septum was preserved. (C): Horien® Gennu-Plug collagen plug was inserted and conventional crossed mattress suturing sealed the wound after the removal of granulated tissue. The collagen retained the blood clot significantly and reduce the hemorrhage. (D): Suturing removal after 7 days and then record.

Discussion

Cigarette smoking has been confirmed to impair oral and periodontal health in literature and studies. In 2018, Rakhshan V presented the risk of alveolar osteitis in patients smoking tobacco². In the same year, Alexandridi et al reported that smoking may decrease the success of periodontal treatment¹⁸. Chaffee et al also reported that wound healing may also be effected due to the use of tobacco and nicotine products in 2021¹. Betel quid chewing is another problem that may lead to serious destruction of oral health and is highly related to the progression of oral cancer¹⁹. In 2008, Akhter et al reported the use of betel quid additives enhances periodontitis leading to the loss of teeth in Bangladesh^{20,21}. However, there is no significant evidence to prove that betel quid chewing disturbs the wound healing process.

Atraumatic extraction has become a routine of clinical practice. The method allows the preservation of uninfected gingival tissue and alveolar bony structure in exodontia and favors the site for future dental implantation or any oral rehabilitation⁷⁻⁹. In 2022, Alraqibah et al presented the benefits of using the periosteal to perform tooth extraction due to short operating time and lower post-operative pain¹¹. For posterior tooth extractions, the preservation of the interradicular septum is advised to obtain better clot formation and maintain the maximum alveolar housing^{7,22,23}. The remain of interradicular septum could divide the wound socket into smaller defects and optimize the healing process⁷. Preserving the interradicular septum during tooth extraction is also suggested in immediate dental implantation^{24,25}. In 2021, Bleyan et al reported the ideal position of immediate implants in molar extraction sockets often require the osteotomy to be in the interradicular septum and resulted in a cumulative implant survival rate of 93.1%²⁴.

The socket-plug technique is able to protect soft and hard tissue during tooth extraction and perform ARP at the same time^{5,6}. Collagen-embedded grafting materials benefit wound healing, reduce chances of hemorrhage and induce better clot formation^{7,17,26}. The collagen materials could lower the risk of the volume loss of the alveolar ridge during the bone remodeling phase compared to spontaneous healing^{7,27,28}. In 2011, Kim et al reported the usage of collagen sponge with xenograft could

prevent horizontal resorption of the alveolar ridge²⁹. In 2020, Morelli et al investigated the volume changes of extracted sockets filled with deproteinized bovine bone and collagen matrix and reported the reduction of buccal soft tissue loss after 6 months³⁰.

Anticoagulants and antiplatelet medications are used for the secondary prevention of cardiac and cerebrovascular diseases that could cause thrombosis^{31,32}. Management of bleeding during and after teeth extraction is certain. The general agreement is that simple tooth extraction with older anticoagulants such as warfarin and antiplatelet agents like clopidogrel, aspirin, ticlopidine, ticagrelor and etc. should not be altered before the procedure^{31,33,34}. Risk of stopping antiplatelet therapy and predisposing the patient to thromboembolic events overweighs the risk of hemorrhage in tooth extraction^{35,36}.

Conclusion

The healing process should be well-taken with care in order to establish primary and secondary wound closure. Cigarette smoking and betel quid chewing cessation should be advised and induced in the patients. The atraumatic extraction procedure is recommended to perform in every exodontia with specific surgical protocols. Within the limits of the study, collagen plug materials reduce wound hemorrhage, benefit clot formation, and maintain alveolar ridge compared to spontaneous healing after the exodontia. These collagen biomaterials are suggested to be applied to patients taking antithrombotic medications and carefully monitored in post-operative healing.

Conflicts of Interest

The authors declare no conflict of interest either directly or indirectly, in the materials or information listed in the article.

References

- Chaffee BW, Couch ET, Vora MV, Holliday RS. Oral and periodontal implications of tobacco and nicotine products. *Periodontol 2000* 2021;87(1):241-253.
- Rakhshan V. Common risk factors of dry socket (alveolitis osteitis) following dental extraction: A brief narrative review. *J Stomatol Oral Maxillofac Surg* 2018;119(5):407-411.
- Kusnierek W, Brzezinska K, Nijakowski K, Surdacka A. Smoking as a Risk Factor for Dry Socket: A Systematic Review. *Dent J (Basel)* 2022;10(7):121.
- Oghli AA, Steveling H. Ridge preservation following tooth extraction: a comparison between atraumatic extraction and socket seal surgery. *Quintessence Int* 2010;41(7):605-609.
- Kotsakis G, Markou N, Chrepa V, Prasad H, Hinrichs J. Alveolar ridge preservation utilizing the socket plug technique. *Int J Oral Implantol Clin Res* 2012;3(1):24-30.
- Kotsakis G, Markou N, Chrepa V, Prasad H, Hinrichs J. Flapless alveolar ridge preservation utilizing the "socket-plug" technique: clinical technique and review of the literature. *J Oral Implantol* 2014;40(6):690-698.
- Hung CC. The Socket-Plug Technique and Materials Comparison in Atraumatic Extractions - A Multiple-Case Study. *SVOA Dentistry* 2023;4(2):45-51.
- Sharma SD, Vidya B, Alexander M, Deshmukh S. Periosteal as an Aid to Atraumatic Extraction: A Comparative Double Blind Randomized Controlled Trial. *J Maxillofac Oral Surg* 2015;14(3):611-615.
- Dietrich T, Schmid I, Locher M, Addison O. Extraction force and its determinants for minimally invasive vertical tooth extraction. *J Mech Behav Biomed Mater* 2020;105:103711.

10. Makki AZ, Nassar AA, Alharbi WM, et al. Evaluation of post-extraction healing after atraumatic axial tooth extraction using Benex system II versus conventional extraction: Randomized control trial. *Saudi Dent J* 2021;33(8):923-928.
11. Alraqibah MA, Rao JKD, Alharbi BM. Periotome versus piezotome as an aid for atraumatic extraction: a randomized controlled trial. *J Korean Assoc Oral Maxillofac Surg* 2022;48(6):356-362.
12. Hammerle CHF, Araujo MG, Simion M, Osteology Consensus Group 2011. Evidence-based knowledge on the biology and treatment of extraction sockets. *Clin Oral Implants Res* 2012;23(5):80-82.
13. Araujo MG, da Silva JCC, de Mendonca AF, Lindhe J. Ridge alterations following grafting of fresh extraction sockets in man. A randomized clinical trial. *Clin Oral Implants Res* 2015;26(4):407-412.
14. Jafer MA, Salem RM, Hakami FB, et al. Techniques for Extraction Socket Regeneration for Alveolar Ridge Preservation. *J Contemp Dent Pract* 2022;23(2):245-250.
15. Finn MD, Schow SR, Schneiderman ED. Osseous regeneration in the presence of four common hemostatic agents. *J Oral Maxillofac Surg* 1992;50(6):608-612.
16. Kotsakis GA, Salama M, Chrepa V, Hinrichs JE, Gaillard P. A randomized, blinded, controlled clinical study of particulate anorganic bovine bone mineral and calcium phosphosilicate putty bone substitutes for socket preservation. *Int J Oral Maxillofac Implants* 2014;29(1):141-151.
17. Fabbro MD, Tommasato G, Pesce P, et al. Sealing materials for post-extraction site: a systematic review and network meta-analysis. *Clin Oral Investig* 2022;26(2):1137-1154.
18. Alexandridi F, Tsantila S, Pepelassi E. Smoking cessation and response to periodontal treatment. *Aust Dent J* 2018;63(2):140-149.
19. Kumar M, Nanavati R, Modi TG, Dobariya C. Oral cancer: Etiology and risk factors: A review. *J Cancer Res Ther* 2016;12(2):458-463.
20. Akhter R, Hassan NMM, Aida J, Takinami S, Morita M. Relationship between betel quid additives and established periodontitis among Bangladeshi subjects. *J Clin Periodontol* 2008;35(1):9-15.
21. Akhter R, Hassan NMM, Aida J, Zaman KU, Morita M. Risk indicators for tooth loss due to caries and periodontal disease in recipients of free dental treatment in an adult population in Bangladesh. *Oral Health Prev Dent* 2008;6(3):199-207.
22. Anitua E, Orive G. A new approach for atraumatic implant explantation and immediate implant installation. *Oral Surg Oral Med Oral Pathol Oral Radiol* 2012;113(3):19-25.
23. Milenkovic J, Vasiljevic M, Jovicic N, Milovanovic D, Selakovic D, Rosic G. Criteria for the Classification of the Interradicular Septum Shape in Maxillary Molars with Clinical Importance for Prosthetic-Driven Immediate Implant Placement. *Diagnostics (Basel)* 2022;12(6):1432.
24. Bleyan S, Gaspar J, Huwais S, et al. Molar Septum Expansion with Osseodensification for Immediate Implant Placement, Retrospective Multicenter Study with Up-to-5-Year Follow-Up, Introducing a New Molar Socket Classification. *J Funct Biomater* 2021;12(4):66.
25. Sayed AJ, Shaikh SS, Shaikh SY, Hussain MA. Inter radicular bone dimensions in primary stability of immediate molar implants-A cone beam computed tomography retrospective analysis. *Saudi Dent J* 2021;33(8):1091-1097.
26. Feng L, Zhang L, Cui Y, et al. Clinical evaluations of mineralized collagen in the extraction sites preservation. *Regen Biomater* 2016;3(1):41-48.
27. Barone A, Ricci M, Tonelli P, Santini S, Covani U. Tissue changes of extraction sockets in humans: a comparison of spontaneous healing vs. ridge preservation with secondary soft tissue healing. *Clin Oral Implants Res* 2013;24(11):1231-1237.
28. Ortiz GA, Chambrone L, Vignoletti F. Effect of alveolar ridge preservation interventions following tooth extraction: A systematic review and meta-analysis. *J Clin Periodontol* 2019;46(21):195-223.
29. Kim YK, Yun PY, Lee HJ, Ahn JY, Kim SG. Ridge preservation of the molar extraction socket using collagen sponge and xenogeneic bone grafts. *Implant Dent* 2011;20(4):267-272.
30. Morelli T, Zhang S, Monaghan E, Moss KL, Lopez B, Marchesan J. Three-Dimensional Volumetric Changes After Socket Augmentation with Deproteinized Bovine Bone and Collagen Matrix. *Int J Oral Maxillofac Implants* 2020;35(3):566-575.
31. Tabrizi R, Akhlaghi F, Khareshi I, Amirhassani S. Do antiplatelet drugs increase the risk of bleeding after tooth extraction? A case-crossover study. *Int J Oral Maxillofac Surg* 2017;46(11):1475-1478.
32. Lu SY, Lin LH, Hsue SS. Management of dental extractions in patients on warfarin and antiplatelet therapy. *J Formos Med Assoc* 2018;117(11):979-986.
33. Schreuder WH, Peacock ZS. Antiplatelet therapy and exodontia. *J Am Dent Assoc* 2015;146(11):851-856.
34. Doganay O, Atalay B, Karadag E, Aga U, Tugrul M. Bleeding frequency of patients taking ticagrelor, aspirin, clopidogrel, and dual antiplatelet therapy after tooth extraction and minor oral surgery. *J Am Dent Assoc* 2018;149(2):132-138.
35. Darawade DA, Kumar S, Desai K, Hasan B, Mansata AV. Influence of aspirin on post-extraction bleeding - A clinical study. *J Int Soc Prev Community Dent* 2014;4:63-67.
36. Halley D, Moore RW, Duane B. No evidence for stopping long-term aspirin therapy before tooth extraction. *Evid Based Dent* 2015;16(4):118-119.