

Operculectomy Using 808nm Diode Laser

Shifa Saleem^{1*} and Shibi Saleem²

¹Department of Dentistry, Irish Wellness Medical Center, Abu Dhabi, UAE

²Department of Dentistry, Taha Medical Center, Abu Dhabi, UAE

Citation: Saleem S, Saleem S. Operculectomy using 808nm Diode Laser. *J Dent Mat* 2023;1(1): 11-13.

Received: 9 June, 2023; **Accepted:** 28 August, 2023; **Published:** 01 September, 2023

***Corresponding author:** Shifa Saleem, Department of Dentistry, Irish Wellness Medical Center, Abu Dhabi, UAE, Email: shifa.saleem@outlook.com

Copyright: © 2023 Saleem S., et al., This is an open-access article distributed under the terms of the Creative Commons Attribution License, which permits unrestricted use, distribution, and reproduction in any medium, provided the original author and source are credited.

ABSTRACT

Introduction: The operculum is a gum flap can form over the top of a fully or partially impacted tooth. It usually covers part of your tooth crown. Food, bacteria and debris can get trapped underneath the operculum and cause infection, called pericoronitis. In such cases, Operculectomy is indicated as treatment, which can be performed with a scalpel (conventional method), an electric scalpel, or a surgical laser.

Objective: To show a clinical case performed at Dental clinic, Irish Wellness Medical Center, Abu Dhabi, UAE, grounded in a literature review.

Case Presentation: A laser operculectomy was performed on a female patient, aged 24, who had severe pain on the lower right back side of the mouth, an indication for operculectomy. The high-power diode laser is excellent for procedures in soft tissue because its wavelength is well absorbed by hemoglobin and other pigments; its use also allows a reduction in the amount of anesthetic and medicines used.

Conclusion: the high power diode laser allowed a satisfactory result, the procedure was safe, the technique was a simple one and of reduced clinical time, as mentioned in the literature. It is worth noting that the technique is dependent on the skill of the professional performing it.

Keywords: Diode lasers; Operculum; Periodontics

Introduction

LASER is an acronym that expands as ‘**Light Amplification by Stimulated Emission of Radiation**’. Gordon Gould is credited with its first introduction in 1959 a graduate student at Columbia University³. Theodore Maiman at Hughes Research Laboratories created the first working laser in 1960. Application of lasers in dentistry varies widely among both soft and hard tissues. Soft tissue applications may include procedures such as a frenectomy, exposure of unerupted teeth, disinfection of root canals among others. Hard tissue applications involve the detection and removal of caries and removal of old restorations.

The diode laser has become an important tool in the dental armamentarium due to its exceptional ease of use and affordability.

It also has key advantages with regard to periodontal treatment. The diode laser is well absorbed by melanin, haemoglobin, and other chromophores that are present in periodontal disease. Hence the diode specifically targets unhealthy gingival tissues. The laser energy is transmitted through a thin fibre that can easily penetrate into deep periodontal pockets to deliver its therapeutic effects¹.

The operculum is a gum flap can form over the top of a fully or partially impacted tooth. It usually covers part of your tooth crown. Food, bacteria and debris can get trapped underneath the operculum and cause infection, called pericoronitis. Pericoronitis may be acute (short-term) or chronic (long-term). Acute pericoronitis symptoms may include Fever, Severe pain

around your back teeth, Redness and swelling of your gum tissue, Pus or drainage, Discomfort when swallowing, Lockjaw (trismus), Facial swelling, Swollen lymph nodes in your neck. Chronic pericoronitis symptoms may include Mild, temporary achiness near your back teeth, Bad breath (halitosis), a bad taste. Operculectomy has been successfully performed and achieved great results by the use of diode lasers¹.

Case Report

A 24 years old female, reported to the dental clinic at Irish Wellness Medical Center, Abu Dhabi, with a chief complaint of severe pain and difficulty in chewing food on the lower right wisdom tooth since the past 1 week. She had consulted another dentist for the same complaint, 6months ago, and was advised to get her wisdom tooth extracted surgically. Clinically, the patient showed good general health with the absence of any relevant medical history.

Intraoral examination revealed the presence of an operculum covering the occlusal surface of the upper right first permanent molar (**Figure 1**).

The operculum was pinkish-brown in colour, firm, resilient and remained tightly adhered to the gingival tissue distal of the lower third molar tooth. No abnormalities were recorded on the radiographic examination of the affected tooth. The results of routine blood investigations were satisfactory.

The patient had a similar history of pain with her lower left wisdom tooth, which was removed surgically. The surgical extraction of lower left wisdom tooth was not very pleasant experience for her and she was apprehensive about pain during the laser operculectomy. Keeping this into consideration, a treatment planning of surgical excision of the operculum with diode laser was made to reduce both treatment time and patient discomfort. Oral prophylactic procedures were carried out before the planned excision. Infiltration anesthesia was given in the region of the lower right wisdom tooth to provide anesthesia to the surrounding soft tissue including the operculum tissue. 2% lidocaine with epinephrine [1:2,00,000] was used for the same. Appropriate eyewear was worn by the dentist, the patient and also the dental assistant before the initiation of the surgical procedure.

Excision of the operculum was started from the distal margin of attachment using a 808nm diode laser – Brand - Elexxon Clarios pico Perio green [manufactured by Dental Ant , Germany]². The parameters used were 2.5 W, in a continuous mode, 808 nm infrared emission [diode laser]; with delivery of the beam through optical fiber 300 µM; energy of 120 J; 20 pps in the presence of a high volume evacuation². The tip of the laser was cleaned regularly during the procedure to remove the adhered scorched tissues. A conscious effort was made to avoid contact between the enamel surface and the laser tip. Satisfactory hemostasis was obtained postoperatively (**Figure 2**).

The surgical site was irrigated with saline to remove any unwanted or remaining debris. The total time required for completion of the procedure was below ten minutes and the patient tolerated the procedure well with minimal pain or discomfort. The patient was advised to use a topical anaesthetic gel at the site of excision and was counselled on the maintenance of appropriate oral hygiene.

A post-operative follow-up after 10 days revealed adequate and uneventful healing (**Figure 3**). A second post-operative follow up was done at 35days, (**Figure 4**) that shows complete

healing. The patient was extremely happy about the fact she did not have to go through the agony of the surgical extraction, that she had to go through during her lower left wisdom tooth extraction and was happy she could save her tooth (**Figure 5**) shows follow up after 1 year.

In this case, the 1 year follow up shows the malposition of the lower right wisdom tooth has not caused cheek bite or traumatic ulcers or other occlusion related problems. The patient is comfortable with the bite and no complaints. Considering this, option of Surgical extraction may be ruled out for this patient.

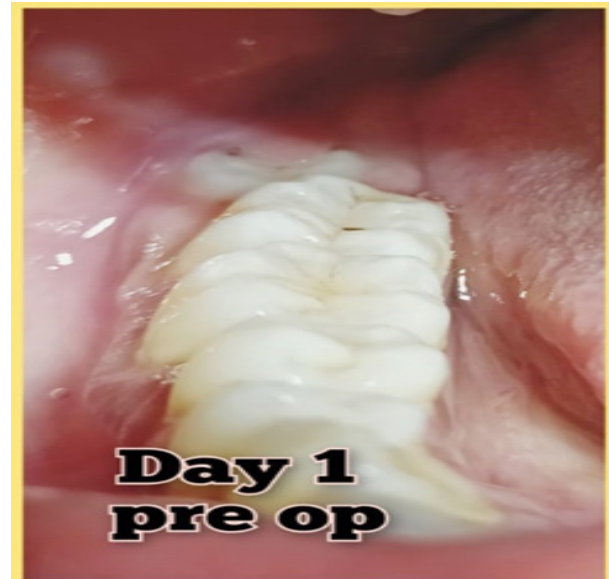

Figure 1. Intraoral examination revealed the presence of an operculum covering the occlusal surface of the upper right first permanent molar.

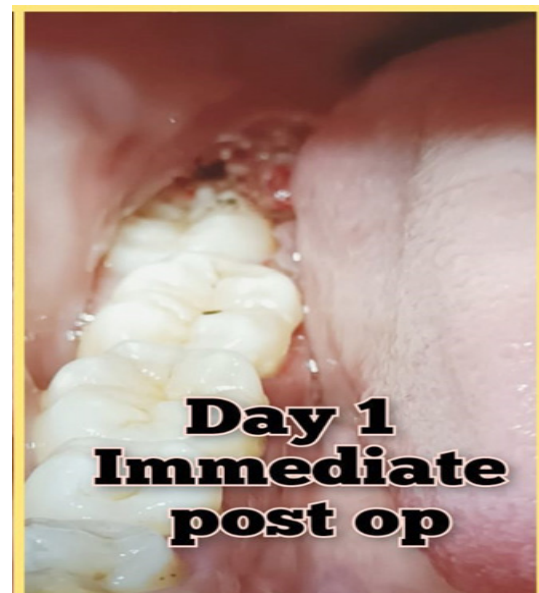


Figure 2. Satisfactory hemostasis was obtained postoperatively.

Discussion

Operculectomy may be referred to as the surgical technique of eliminating the operculum, or the gingival flap that usually covers the occlusal surface of the tooth partially. Operculectomy is aimed to reduce the incidence of pericoronitis, a condition that is marked by pain and inflammation associated with the operculum. Pericoronitis is usually seen among young adults,

mainly in the molar teeth that are beginning to erupt⁴. The patient in our case presented with pain and discomfort in the region of lower right wisdom tooth or the third molar due to the presence of an operculum associated with the tooth. Plaque build-up on the underside of the operculum along with the accumulation of food debris caused inflammation and enlargement of the gingiva. The latter was being easily traumatized at the time of mastication, subsequently causing pain and discomfort. Operculectomy with diode laser was the chosen treatment plan as it presented with numerous advantages over the conventional scalpel surgical procedure. Its benefits in soft tissue surgeries include enhanced accuracy, easily achieved hemostasis, less necrosis of tissue from heat in comparison to electro surgery, the accelerated rate of wound healing, sutureless surgery, decreased post-operative pain, and discomfort with reduced need for analgesics. Most procedures using lasers may be operated with topical local anesthesia alone that results in enhanced patient co-operation along with abridged procedural time. Additionally, the bactericidal effect of lasers on the surgical site means reduced use of antibiotics postoperatively.

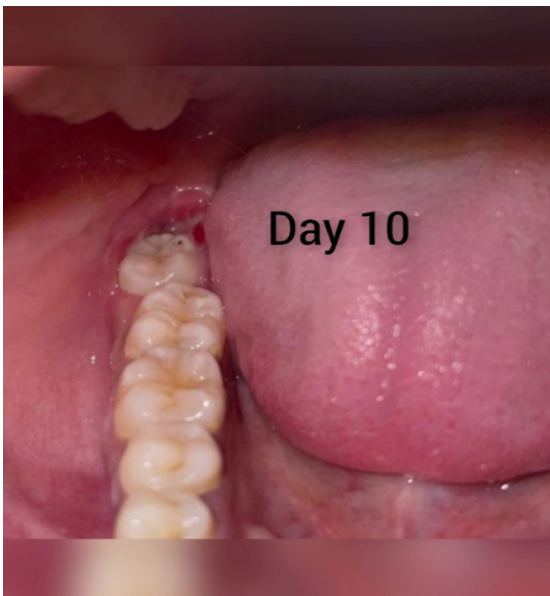

Figure 3. A post-operative follow-up after 10 days revealed adequate and uneventful healing.

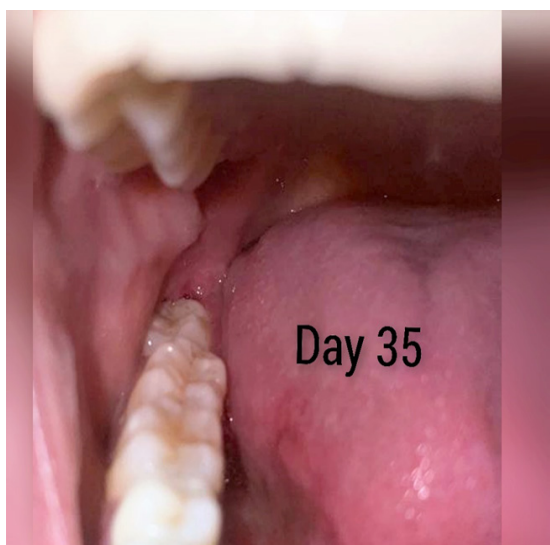

Figure 4. A second post-operative follow up was done at 35days that shows complete healing.

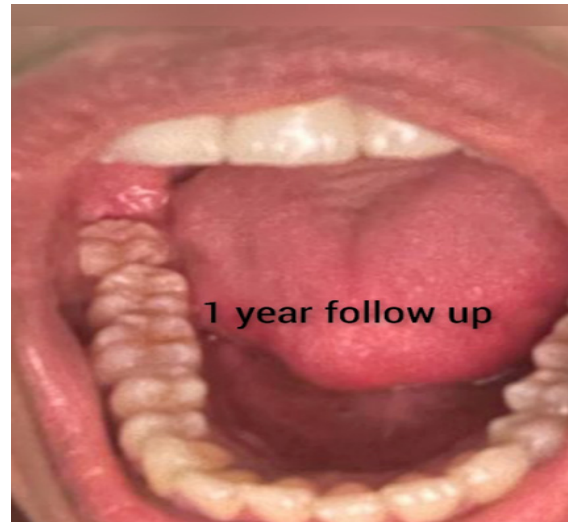

Figure 5. Follow up after 1 year.

Conclusion

Operculectomy is a minor surgical procedure aimed to eliminate the operculum or the gingival tissue flap present over a fully or partially erupted tooth, usually in molars that if left unchecked may lead to pericoronitis and symptoms associated with the latter. Operculectomy using soft tissue lasers may be considered as a more favorable option in every aspect of dentistry involving soft tissue surgeries in comparison to conventional method where patient co-operation and procedural time must be accounted for⁴.

Conflicts of Interest

The authors have declares that there are no conflict of interest.

References

1. Principles and Practice of laser Dentistry - by Robert A. Convisar, Elsevier 2015.
2. Freitas PM, Simones A. Lasers in Dentistry: Guide for Clinical Practice. Wiley 2015.
3. Gross AJ, Herrmann TRW. History of lasers. World J Urol 2007;25(3):217-220.
4. Dodson TB. The management of the asymptomatic, disease-free wisdom tooth: removal versus retention. (review). Atlas Oral Maxillofac Surg Clin North Am 2012;20(2):169-176.